

H. ERNST\*, P. C. KONTUREK\*\*, E. G. HAHN\*\*, H. P. STOSIEK\*, T. BRZOZOWSKI\*,  
S. J. KONTUREK†

## EFFECT OF LOCAL INJECTION WITH BASIC FIBROBLAST GROWTH FACTOR (bFGF) AND NEUTRALIZING ANTIBODY TO bFGF ON GASTRIC ULCER HEALING, GASTRIC SECRETION, ANGIOGENESIS AND GASTRIC BLOOD FLOW

\*\*Departments of Gastroenterology and Pathology, Carl-Thiem-Klinikum, Cottbus, Germany,

\*Department of Medicine I, University of Erlangen-Nuremberg, Erlangen, Germany and

†Department of Physiology, Jagiellonian University School of Medicine, Cracow, Poland

Exogenous administration of bFGF was shown to accelerate tissue repair predominantly due to an increase in the formation of new microvessels (angiogenesis) suggesting that bFGF plays an important role in healing of gastric ulcer. This study was designed: 1) to examine the effect of local application of bFGF with or without neutralizing antibody (NA) to bFGF and 2) to determine the role of gastric secretion, gastric blood flow (GBF) at the ulcer margin and angiogenesis during gastric ulcer healing with or without local application of NA, bFGF or the combination of NA and bFGF. Chronic gastric ulcers were induced in Wistar rats by subserosal application of acetic acid (ulcer area 28 mm<sup>2</sup>) and gastric secretion during ulcer healing was assessed using animals additionally equipped with chronic gastric fistulas. The bFGF without or with NA to bFGF (10 ng/100 µl), irrelevant antibodies (rabbit IgG; 10 µg/100 µl) or vehicle (saline) were locally injected into the subserosa immediately upon ulcer induction (day 0) and at day 2. Rats with acetic acid ulcers without subserosal injections served as controls. At day 11, all animals were anaesthetized and GBF was determined at the ulcer base, ulcer margin as well as in intact mucosa using the H<sub>2</sub>-gas clearance technique and the area of gastric ulcers was measured by planimetry. Gastric mucosa with ulcer was excised and the percentage of area covered with blood vessels, the number of fibroblasts and the percentage of connective tissue at the ulcer edge was assessed by histology. The gastric ulcers were healed spontaneously in control vehicle-treated rats at day 11 and this was accompanied by the significant increase in the GBF and number of microvessels in the ulcer area. The gastric secretion was suppressed immediately after ulcer induction and increased significantly at day 2 and day 11 but failed to return to that recorded in intact animals. In contrast, local application of bFGF inhibited gastric acid and pepsin outputs at each study time intervals tested and this effect was reversed by addition of NA to bFGF. Locally applied bFGF accelerated significantly ulcer healing and this was accompanied by the greater rise in the GBF of ulcer margin and more marked increase in number of microvessels as compared to those in vehicle-treated rats. Subserosal application of NA to bFGF prolonged significantly the ulcer healing and this effect was accompanied by a significant fall in the GBF at the ulcer margin and a decrease in number of capillaries in ulcer bed without significant alteration in gastric acid and pepsin outputs. The ulcer healing effect of bFGF and accompanying increase in the GBF at ulcer margin and in the

number of microvessels as well as inhibition of gastric acid secretion evoked by bFGF were significantly attenuated by the addition of NA to bFGF. The number of fibroblasts and the distribution of connective tissue did not differ between groups studied. We conclude that; 1) depletion of endogenous bFGF at the ulcer area by specific NA to bFGF delays healing of gastric ulcers, reduces angiogenesis of ulcer bed and impairs the microcirculatory effect of this growth factor at the ulcer margin indicating that the availability of bFGF in the ulcer area plays a crucial role in the ulcer healing through induction of angiogenesis; 2) this prominent antiulcer effect of locally applied bFGF depends, at least in part, upon the inhibition of acid secretion by this peptide.

**Key words:** *ulcer healing, basic fibroblast growth factor, gastric blood flow, angiogenesis, neutralizing antibody, gastric secretion.*

## INTRODUCTION

Healing of chronic gastric ulcers is mediated by local as well as systemic growth factors, such as epidermal growth factor (EGF), transforming growth factor- $\alpha$  (TGF $\alpha$ ), platelet derived growth factor (PDGF), transforming growth factor  $\beta$ 1 (TGF $\beta$ 1), hepatocyte growth factor (HGF) and basic fibroblast growth factor (bFGF) (1—8). These growth factors are potent mitogenic peptides that are expressed in a variety of tissues including the gastrointestinal tract (9—12).

Basic fibroblast growth factor (bFGF) was shown to act as one of the most potent angiogenic factor (13). Biological activity of bFGF include the stimulation of the migration and proliferation of various mesenchymal cells including fibroblasts and smooth muscle cells as well as endothelial cells leading to angiogenesis (13). It was proposed that bFGF may play a crucial role in the process of healing of mucosal lesions because this growth factor has been detected in several compartments of the gastrointestinal mucosa, for instance, in superficial epithelial cells throughout the GI tract and in basal lamina and extracellular matrix (2, 9). Two receptor systems for bFGF include a high-affinity system of transmembranous receptors and a low-affinity receptor system, that of the heparin sulfate proteoglycans localized in the extracellular matrix (14).

Previous studies revealed that treatment with an acid-stable recombinant bFGF results in more effective angiogenesis and wound healing in rats (3). This has led to the hypothesis that endogenous bFGF presumably existing in the granulation tissue in the ulcer bed and in the mucosa, might be essential for ulcer healing, due to stimulation of angiogenesis and that acid suppression therapy may enhance the bioavailability of bFGF in the ulcer bed (2). Moreover, oral treatment with exogenous acid bFGF resulted in an acceleration of ulcer healing but gastric acid secretion was not determined during ulcer healing by bFGF. More recently, successful treatment of duodenal ulcers with bFGF has been reported in humans (15).

Recent findings suggest that *Helicobacter pylori* might interfere with the activation of bFGF from extracellular matrix components (16) suggesting that a decrease in locally available bFGF might lead to an impairment in chronic gastric ulcer healing.

In this study we tested the hypothesis that deficiency of growth factor such as bFGF in the ulcer area induced by the application of neutralizing antibodies to bFGF could interfere with the ulcer healing in rats without or with local application of bFGF, and we attempted to examine the role of gastric secretion, gastric blood flow (GBF) and angiogenesis in mechanism of ulcer healing induced by this angiogenic peptide with or without addition of its antibody.

## MATERIALS AND METHODS

### *Animal model*

In all experiments including those with gastric fistula to assess gastric secretion, gastric ulcers were induced in male Wistar rats weighing 180–220 g by the method of acetic acid application to the serosal surface as described in details elsewhere (4, 5). Each group of animals consisted of 6–8 rats.

All animal use in this study was conducted in compliance with approved institutional animal care according to guidelines of Jagiellonian University Ethics Committee and Carl-Thiem-Klinikum, Cottbus, Germany.

### *Gastric secretory studies*

The alterations of gastric secretion during ulcer healing was tested in a separate group of 30 starved rats with acetic acid ulcers, surgically equipped with chronic gastric fistulas (GF) as described previously (4). Control sham-operated rats with GF were also included, but instead of acetic acid, 70  $\mu$ l of saline was applied to the serosal surface of the stomach for 20 s. bFGF (10  $\mu$ g in 100  $\mu$ l of phosphate buffered saline) was injected just around the ulcer immediately after ulcer induction with acetic acid (day 0) and the local application of this growth factor was repeated after laparotomy at day 2 following ulcer induction according to the method described in detail elsewhere (6). After recovery from anesthesia (day 0) or at day 2, and 11 after ulcer induction, GF rats without and with gastric ulcers were placed in the individual Bollman cages to prevent coprophagy and to maintain the necessary restraint. Each GF was then opened, and the stomach rinsed gently with 5–8 ml of tap water at 37°C. Basal gastric secretion was collected for 120 min, during which time the rats received saline at a rate of 4 ml/h subcutaneously (s.c.). The gastric juice was collected every 30 min, the volume was measured, and then the acid and pepsin concentrations and outputs were determined and expressed as the output per 30 min as described previously (17).

### *Experimental design*

Rats with gastric ulcers produced by acetic acid technique as described above for secretory studies, were divided into four groups and treated with local anti-bFGF therapy or controls (as described below). On day 11, they were anesthetized with ether to measure GBF as described

previously (18) and the ulcer area was measured planimetrically (Morphomat, Carl Zeiss, Berlin, Germany). Biopsy samples were excised from the gastric mucosa with ulcer, immersed in 10% buffered formalin then embedded in paraffin and stained with hematoxylin and eosin for histological examination.

### *Local injection with vehicle, bFGF, antibody to bFGF and their combination*

Immediately after the induction of ulcers during laparotomy (day 0), rats were injected subserosally (in the area of application of acetic acid) either with; 1) vehicle (saline), 2) NA to bFGF 10 µg/100 µl, (BDA 4, R&D Systems, Minneapolis, USA), 3) bFGF (10 µg/100 µl), 4) NA to bFGF plus bFGF (10 µl/100 µl each), 4) rabbit IgG-control (10 µg in 100 µl, R&D Systems, Minneapolis, USA). In order to check, whether submucosal injection itself could influence ulcer healing, sham-operated animals with gastric ulcers but without any submucosal injections were also employed.

On day 2, the laparotomy was performed and the vehicle, NA to bFGF, bFGF and the combination of NA to bFGF together with bFGF were again injected locally into the ulcer area. These subserosal injections comprised the respective substance in phosphate-buffered saline at a volume of 100 µl as mentioned above, and again these growth factors and vehicle (saline) were applied just around the ulcer localized on anterior wall of the stomach. The specificity of the NA against bFGF has been tested in our preliminary experiments by employing direct ELISA, Western Blot analysis and the neutralization of the biological activity of bFGF with BDA 4 using NR6 fibroblasts.

### *Determination of ulcer size and depth*

The area of the ulceration was measured planimetrically by a person who was blinded to the origin of the coded specimens, using a computerizing planimeter (Morphomat 10, Opton, F.R.G.), and results expressed in square millimeters. The sections were embedded in paraffin and stained with hematoxylin and eosin (H&E). In addition to measuring the surface area of the ulcer in square millimeters, a scale of 0—3 was used to assess the depth of the residual ulcer (0 — complete healing of the ulcer; 1 — superficial erosion; 2 — deep ulcer extending into the muscularis; and 3 — penetrating or perforating ulcer) according to the method proposed elsewhere (3).

### *Determination of matrix score and morphometric analysis of number of capillaries and fibroblasts*

The area of dense connective tissue fibers material in the gastric ulcer bed in the trichrome stained sections was assessed by a semiquantitative score as described before (19). This was expressed as the percentage of submucosal area covered by dense connective tissue fibers material. Three submucosal areas beneath the ulcer were selected (25 point raster; with a x 20 objective) by two independent observers. The results were pooled for statistical analysis.

Capillaries and fibroblasts were identified in the H&E stain and were counted per low power x20 objective field (per 25 point raster) in the ulcer bed according to the method described in detail before (20).

### *Statistical analysis*

For statistical analysis the nonparametric Mann-Whitney U and Kruskal-Wallis tests for unpaired comparisons were applied where appropriate with a p value < 0.005 taken as significant.

## RESULTS

*Effect of bFGF with or without the combination with NA to bFGF on gastric secretion during the ulcer healing*

The results of gastric secretory studies in conscious rats equipped with gastric fistula with or without induction of gastric ulcers are presented in *Table 1*. In control rats without gastric ulcers, the basal acid output averaged  $132 \pm 11$   $\mu\text{mol}/30$  min, and pepsin output reached the value of  $0.98 \pm 0.15$  mg/30 min. Immediately after induction of gastric ulcers, the gastric acid and pepsin outputs were significantly reduced by about 55% and 42%, respectively, as compared with the values recorded in control rats without ulcer induction. Local application with bFGF resulted in a further significant decrease in gastric acid and pepsin outputs as compared to those injected submucosally with vehicle (saline) (*Table 1*). NA to bFGF applied alone failed to affect

*Table 1.* Effect of submucosal injection with vehicle (saline), bFGF and neutralizing antibody (NA) to bFGF on gastric acid secretion in rats with gastric ulcers equipped with gastric fistula. Results are Means  $\pm$  SEM of 8–10 rats. Asterisk indicates a significant change as compared with the value obtained in intact animals. Cross indicates a significant increase as compared to the value obtained in vehicle control animals at respective days upon ulcer induction.

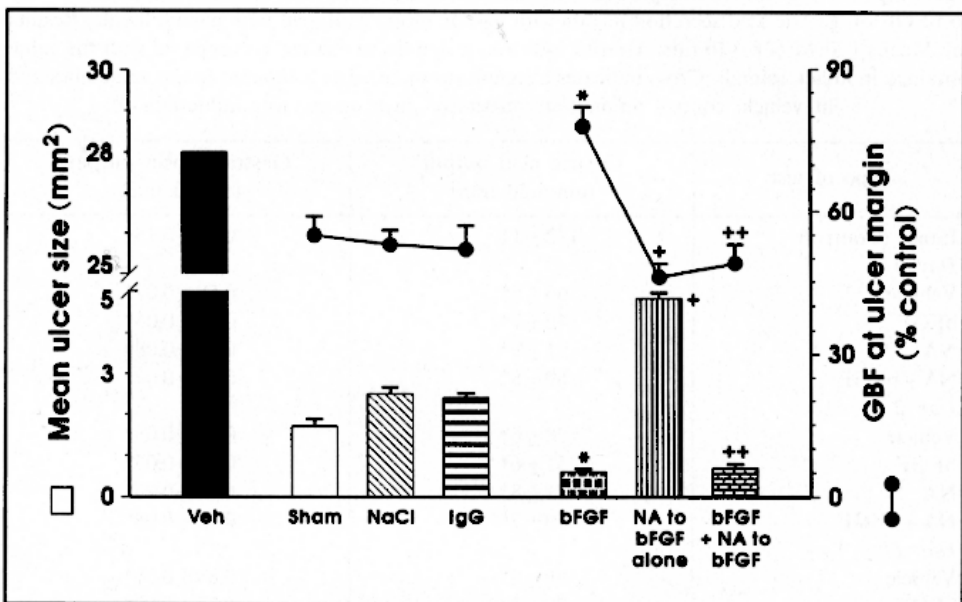
Type of test	Gastric acid output ( $\mu\text{mol}/30$ min)	Gastric pepsin output (mg/30 min)
Intact (Control)	$132 \pm 11$	$0.98 \pm 0.15$
Day 0		
Vehicle	$66 \pm 5^*$	$0.58 \pm 0.07^*$
bFGF	$42 \pm 7^{*+}$	$0.41 \pm 0.05^{*+}$
NA	$71 \pm 9^*$	$0.60 \pm 0.08^*$
NA + bFGF	$69 \pm 8^*$	$0.62 \pm 0.07^*$
Day 2		
Vehicle	$78 \pm 6^*$	$0.72 \pm 0.06^*$
bFGF	$51 \pm 6^{*+}$	$0.61 \pm 0.05^{*+}$
NA	$81 \pm 8^*$	$0.74 \pm 0.06^*$
NA + bFGF	$79 \pm 7^*$	$0.72 \pm 0.08^*$
Day 11		
Vehicle	$96 \pm 8^*$	$0.88 \pm 0.06^*$
bFGF	$75 \pm 5^{*+}$	$0.78 \pm 0.07^{*+}$
NA	$103 \pm 8^*$	$0.90 \pm 0.05^*$
NA + bFGF	$105 \pm 7^*$	$0.87 \pm 0.07^*$

significantly the acid and pepsin output as compared to the values recorded in vehicle-injected animals. On day 2, the gastric secretion in vehicle-treated rats tended to increase but still significant inhibition of gastric acid and pepsin outputs was observed as compared to those in intact rats without gastric

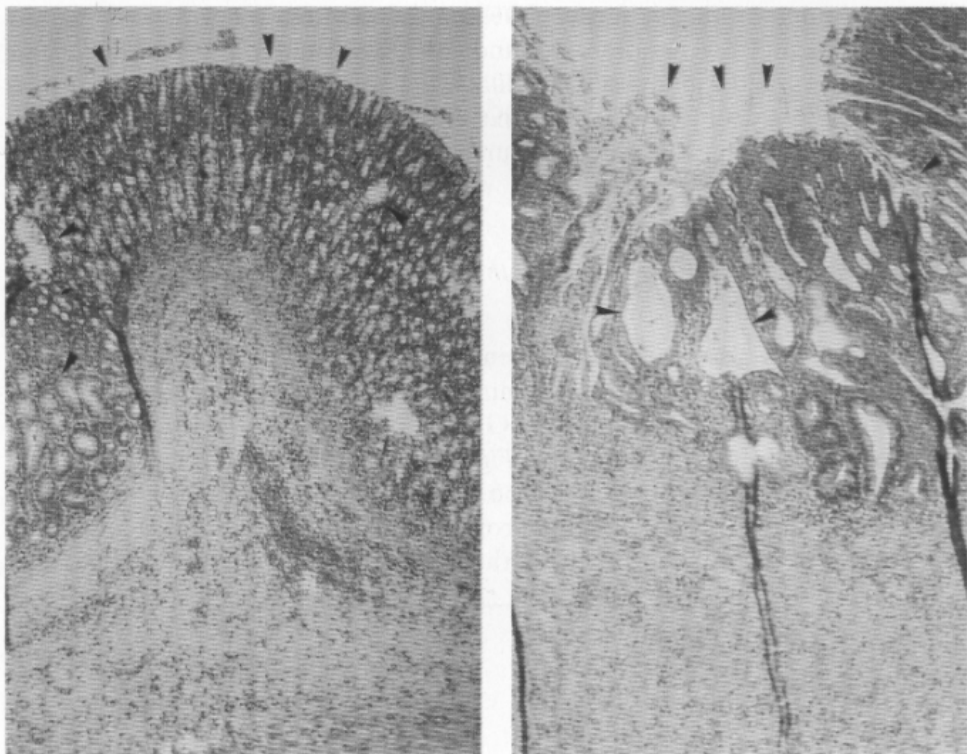
ulcers. Submucosal injection of bFGF reduced significantly gastric acid and pepsin output below the values obtained in those injected submucosally with vehicle while submucosal injection with NA to bFGF had no significant effect. After 11 days, the values of gastric acid and pepsin outputs in rats injected submucosally with vehicle were still significantly lower as compared to those obtained in rats without ulcer. In rats injected submucosally with bFGF a further decrease in the gastric acid and pepsin outputs was still observed as compared to vehicle-treated controls and this effect was abolished at each study point by concurrent treatment with NA to this growth factor (*Table 1*).

*Effect of local injection of bFGF, NA to bFGF and their combination on ulcer healing and the GBF in the ulcer area*

As shown in *Fig. 1*, in sham-operated rats with gastric ulcers but without submucosal injection the area of gastric ulcer at day 11 upon ulcer induction was significantly reduced by 78% as compared to the initial area at day 0



*Fig. 1.* Mean ulcer size and gastric blood flow (GBF) at ulcer margin at day 11 after ulcer induction in rats with gastric ulcer injected locally with NaCl, irrelevant antibody (IgG), bFGF or neutralizing antibody (NA) alone and those injected with NA applied in the combination with bFGF. Sham controls were animals with gastric ulcers without submucosal injections. Mean  $\pm$  SEM of 6–8 rats. Asterisk indicates a significant change as compared to the value obtained in sham-controls or those injected with NaCl or IgG. Cross indicates a significant change as compared to the value obtained in gastric mucosa injected with respective controls or bFGF. Double cross indicates a significant change as compared to the value obtained in animals injected with bFGF alone.



**Fig. 2 A, B.** Microscopic appearance acetic acid-induced gastric ulcer in animals injected with vehicle (saline) or neutralizing antibody (NA) to bFGF at day 11 upon ulcer induction. The mucosal surface is restored as reflected by mucosal scar, however the gastric glands became dilated and glandular structure remains abnormal by histology (arrows) (A). In rats injected with NA to bFGF, the ulcer healing is not completed as evidenced by failure to form mucosal scar, less granulation tissue and more abnormalities in the glandular structure (arrows) (B).

and this inhibition was similar to that recorded in animals injected with vehicle (saline) or those injected with rabbit IgG. The GBF at the ulcer margin was significantly higher than that in the ulcer base but remained not significantly different than that in the non-ulcerated adjacent gastric mucosa. Submucosal application of bFGF around the ulcer produced a decrease in the area of this ulcer and raised the GBF at ulcer margin as compared to those animals injected with vehicle (*Fig. 1*). In contrast, local injection with NA to bFGF alone raised significantly the area of gastric ulcers and produced a significant fall in the GBF at ulcer margin as compared to those recorded in vehicle-treated rats. The addition of NA to bFGF abolished the acceleration of ulcer healing and accompanying rise in the GBF evoked by bFGF alone (*Fig. 1*). The representative example of the healing of acetic acid induced gastric ulcer in vehicle-injected animals at day 11 upon ulcer induction is presented in *Fig. 2 A*.

The continuity of the surface epithelium is restored as evidenced by the mucosal scar and regeneration of glandular architecture, however this healed mucosa shows abnormally looking dilated gastric glands. In contrast, in rats treated with NA to bFGF the ulcer healing is delayed as reflected by the not complete restoration of mucosal surface and more abnormalities in the glandular structure (Fig. 2 B).

*Histological assessment of ulcer depth and number of new microvessels and fibroblasts at ulcer bed*

The results of histological assessment of depth of gastric ulcers revealed that necrotic debris surrounded by inflammatory cells were observed in all ulcer craters of rats treated with vehicle, bFGF and NA without or with concomitant treatment with bFGF. As shown in Fig. 3, histological assessment of residual ulcers by a score established by Szabo *et al.* (3) revealed that despite the fact that the ulcer area was increased in group treated with NA to bFGF at day 11 upon ulcer induction, the depth of the residual ulcers was not significantly

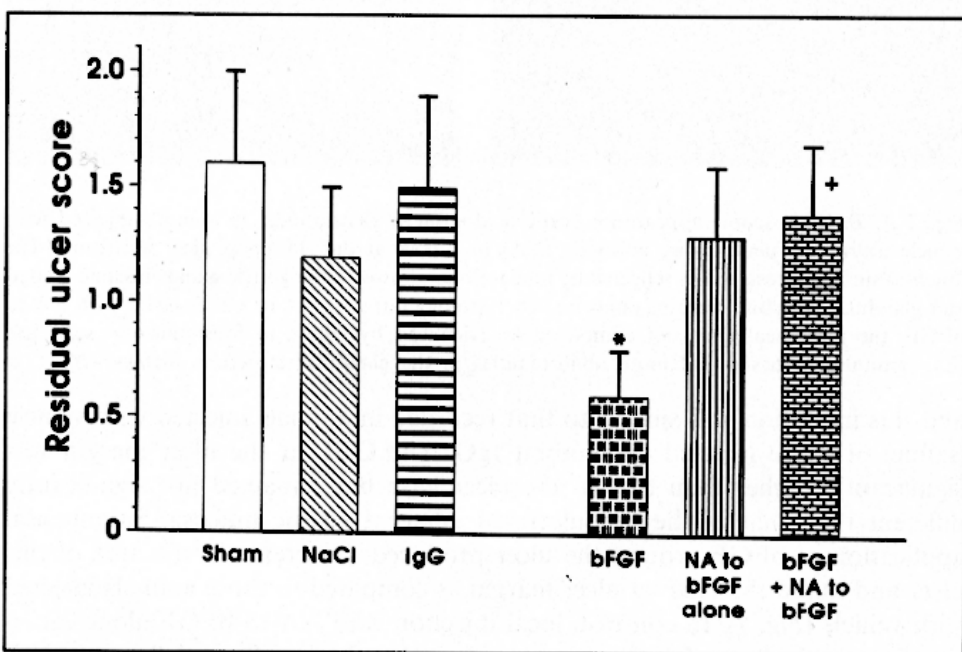


Fig. 3. Effect of local injection with NaCl, irrelevant antibody (IgG), bFGF or neutralizing antibody (NA) alone and those injected with NA applied in the combination with bFGF on residual ulcer score as determined at day 11 upon ulcer induction. Mean  $\pm$  SEM of 6–8 rats. Asterisk indicates a significant change as compared to the value obtained in sham-controls or those injected with NaCl and IgG. Cross indicates a significant change as compared to the value obtained in gastric mucosa injected with bFGF applied alone.



affected by the antibody against bFGF. In contrast, local injection with bFGF reduced significantly the depth of residual ulcers and this was significantly attenuated by addition of NA to bFGF (Fig. 3).

The number of capillaries in the ulcer bed and ulcer margin of rats treated with bFGF was significantly increased as compared to sham-operated controls and those injected with respective vehicle or irrelevant antibody (rabbit IgG) (Fig. 4). In contrast, NA to bFGF applied locally resulted in significant decrease in the number of microvessels as compared to those injected locally with vehicle and abolished completely the rise in the number of microvessels produced by bFGF (Fig. 4).

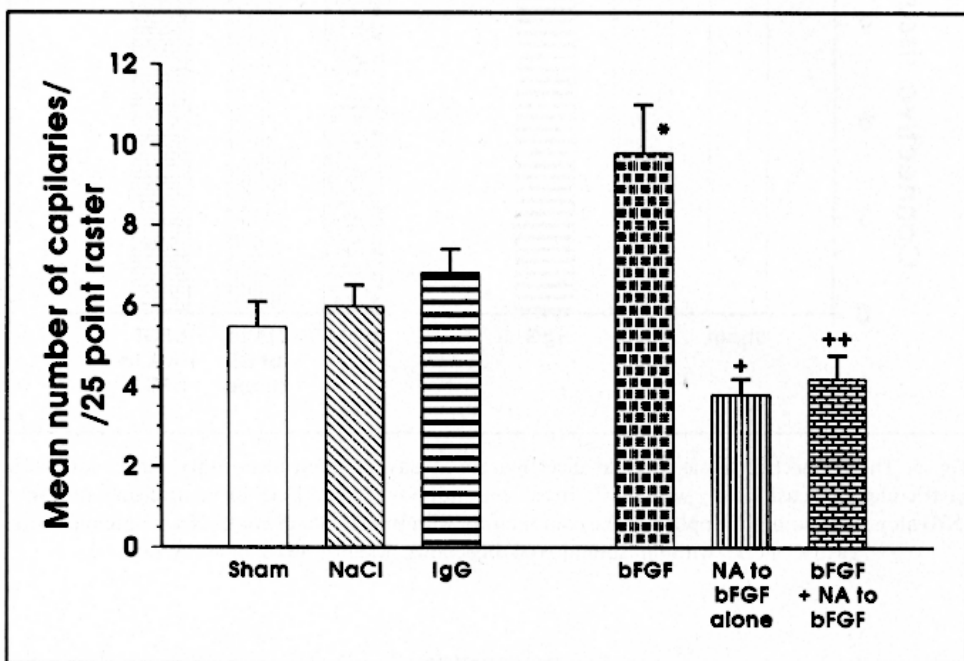


Fig. 4. Mean number of capillaries at ulcer margin in rats with gastric ulcer injected locally with NaCl, irrelevant antibody (IgG), bFGF or neutralizing antibody (NA) alone and with NA applied in the combination with bFGF. Sham controls were animals with gastric ulcers without submucosal injections. Mean  $\pm$  SEM of 6–8 rats. Asterisk indicates a significant change as compared to the value obtained in sham-controls or those injected with NaCl or IgG. Cross indicates a significant change as compared to the value obtained in gastric mucosa injected with respective controls or bFGF. Double cross indicates a significant change as compared to the value obtained in animals injected with bFGF alone.

The matrix score, assessing connective tissue fibers in the ulcer bed in the sham-operated controls and those injected locally with vehicle, bFGF and NA applied alone or added to bFGF failed to show any difference in the

distribution of connective tissue fibers in the submucosa of the ulcer bed (Fig. 5). Density of fibroblasts in the ulcer bed was not significantly different in each group studied (Fig. 5).

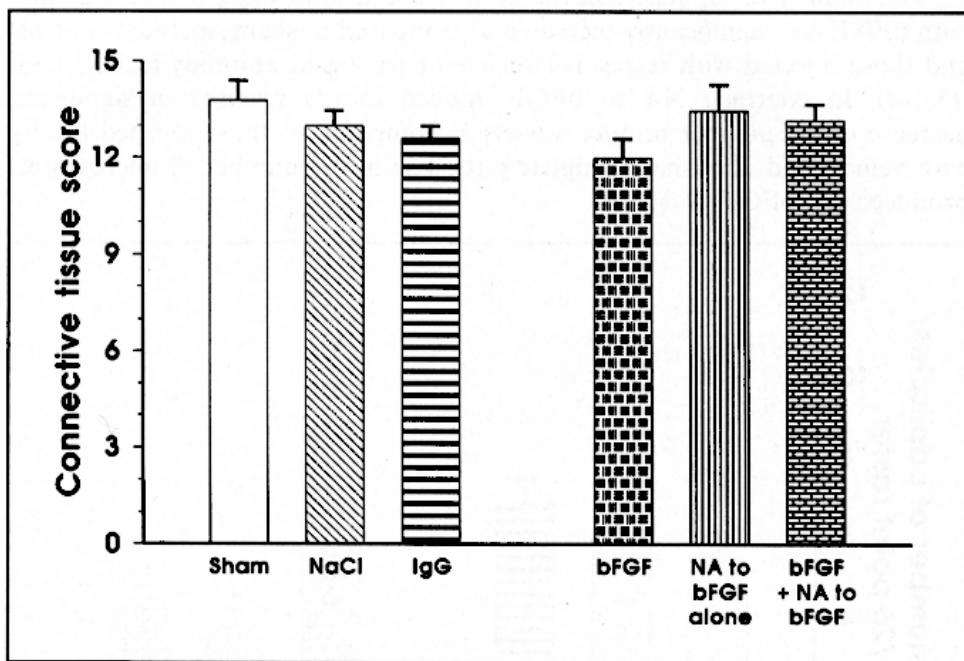


Fig. 5. The connective tissue score at ulcer margin at day 11 upon ulcer induction in rats with gastric ulcer injected locally with NaCl, irrelevant antibody (IgG), bFGF or neutralizing antibody (NA) alone and with NA applied in the combination with bFGF. Sham controls were animals with gastric ulcers without submucosal injections. Mean  $\pm$  SEM of 6–8 rats.

## DISCUSSION

This study shows that the local administration of neutralizing antibodies against bFGF led to a delay in spontaneous healing of chronic gastric ulcers indicating that endogenous bFGF generated in the area surrounding ulceration contributes to healing of this ulcer. Although the mechanisms of ulcer healing have not yet been fully explained, it is assumed that the general principles of wound healing largely apply also to ulcer healing. Thus, the healing of gastric ulcerations is based on a complex interplay of cell matrix interactions, cell proliferation, cell migration and angiogenesis (20). For angiogenesis, various polypeptides such as bFGF, angiogenin, TGF $\alpha$ , TGF $\beta$ , TNF $\alpha$ , PDGF and angiotropin play a pivotal role in the induction of proliferation and differentiation of endothelial cells (1–6, 13). Among these

angiogenic factors, bFGF is currently the best characterized and found to be present in a wide range of structures of the gastrointestinal tract including gastric mucosa. Oral administration of acid-stable bFGF has been shown to accelerate the healing of gastroduodenal ulcerations produced by acetic acid or cysteamine. It was proposed that endogenous bFGF present in the region of the ulcer plays an important role in healing of gastric ulcers (13, 20).

Despite the present interest in *H. pylori* as a pathogen in the development and recurrence of peptic ulcers, no plausible explanation as to how this organism might lead to the formation of chronic ulcer has so far been provided. Interestingly, however, investigations into the interaction between *H. pylori* and heparin and heparin-dependent growth factors have shown that *H. pylori* is able to bind bFGF and this may contribute to the reduction in the local peptide availability (16). In our study, we show for the first time that local application of bFGF by subserosal injection of this peptide into ulcer area accelerates ulcer healing and this effect is accompanied by the suppression of gastric acid secretion and the rise in the GBF at ulcer margin. Moreover, the local application of specific antibodies against bFGF which by itself failed to influence gastric acid secretion, delayed ulcer healing and attenuated the rise in the blood flow at the margin of gastric ulcer suggesting that elimination of this peptide from the ulcer area interferes with spontaneous healing process, resulting in a significant prolongation of the ulcer healing. We confirmed previous observation (20) that parenteral administration of bFGF leads to a significant increase in the blood flow at the margin of gastric ulcer suggesting that this hyperemia at ulcer margin could be responsible for the increase in the healing rate observed in rats treated with this peptide. This notion is supported by the fact that local injection with neutralizing antibodies against bFGF together with bFGF abolished both the acceleration of the ulcer healing and the accompanying rise in the GBF at ulcer margin induced by bFGF alone. Moreover, the treatment with antibody against bFGF produced a significant decrease in the number of newly formed capillaries in the ulcer area and significantly reversed the increase in the number of these microvessels produced by bFGF. This indicates that an impairment of the microcirculation of ulcer margin and inhibition of angiogenesis could be reasonable explanation for the delay in ulcer healing observed in animals treated with antibody against bFGF applied alone and combined with this growth factor. Local treatment with antibodies against bFGF added to bFGF eliminated the beneficial effect of this growth factor on ulcer healing and accompanying increase in microcirculatory response in the ulcer area as well as angiogenesis indicating that bFGF plays an essential role in the mechanism of ulcer healing and in the process of the formation of new microvessels in the granulation tissue at the ulcer bed. This was also confirmed by histology showing failure of ulcer healing and mucosal scar formation in animals locally injected with antibodies against bFGF as

compared with those injected with vehicle or bFGF. Removal of this endogenous growth factor from the crucial place for ulcer healing such as ulcer margin results in prolongation of the healing process and seems to be responsible for the poor quality of ulcer healing observed in rats injected locally with antibody against bFGF.

It has been shown that bFGF contributes to the angiogenesis by promoting the reinnervation of newly formed microvessels. Although we did not attempt in this report to study the effect of bFGF and its antibody on the reinnervation of gastric vessels, insufficient autonomic innervation may be a further reason for suppression of blood flow in the ulcer edge in rats treated with neutralizing antibody against bFGF.

Our previous immunostaining study demonstrated that bFGF was detected in the surface epithelial cells, basement membranes, the connective tissue and the *muscularis mucosae* (9). We confirmed that immunoreactivity of bFGF was detected in the connective tissue, fibroblasts and endothelial cells following the healing of chronic gastric ulcers. The mechanism of liberation of bFGF from the cytoplasm remains, however, unclear. A conceivable mechanism might be liberation of bFGF following cellular damage by mechanical means or the effects of chemical irritants (21).

Two types of receptors and storage systems are known for bFGF (14), a high affinity transmembrane receptors and a low affinity receptor system, involving of the heparin sulfate proteoglycans. Proteoglycans are proteins containing a carbohydrate chain and are part of the extracellular matrix (ECM). Numerous proteoglycans act as modulators of growth factors. Binding of bFGF to heparin or heparin sulfate chains of proteoglycans protects this growth factor from degradation (14). Released by heparinases from activated platelets or neutrophil granulocytes, bFGF can be generated by proteolysis of proteoglycan core proteins or by partial degradation of the heparin sulfate chains. In chronic gastric ulcers, loss of the mucosal barrier, may give proteolytic enzymes access to ECM in the lamina propria and submucosa leading to conversion of non-active bFGF to its active form.

Delayed healing of gastric ulcers after local injection of a neutralizing antibody to bFGF provides indirect evidence that endogenous bFGF at the ulcer site is critical for the initiation and maintenance of ulcer healing process. Further evidence that endogenous bFGF may play an important role in ulcer healing comes from a study by Szabo and coworkers, who used a different approach to suppress activity of bFGF (22). They injected a monoclonal antibody against bFGF intraperitoneally or intravenously into rats, and these injections also resulted in a significant delay in ulcer healing (22). This intraperitoneally injection may largely affect the release of bFGF from the *omentum* as originally proposed (20). The *omentum* attached to the ulcer area was found to accelerate ulcer healing in a manner similar to that observed after

parenteral administration of bFGF (20). Furthermore it was shown that *omentum* contains bFGF and that attachment of *omentum* to the serosal side of gastric ulcer bed led to a significant increase in gastric blood flow at the ulcer margin (20). Intravenously injected monoclonal antibodies against bFGF may have both systemic and local effect on ulcer healing (22) while in our study submucosal application predominantly was expected to activate the ulcer healing process locally. It remains to be established whether such local application of bFGF humans could enhance healing process of gastroduodenal ulcerations without necessity of using potent gastric acid inhibitors.

In summary, local application of NA to bFGF to the ulcer area resulted in prolongation of the ulcer healing, and the fall in gastric blood flow as well as in angiogenesis in the ulcer area. This study provides a further evidence for the importance of endogenous bFGF in the mechanism of gastric ulcer healing and may be of therapeutically important in light of further clinical studies in humans.

*Acknowledgement:* This work was supported by a grant from the Doctor Robert Pfleger-Stiftung and the J and F Marohn-Stiftung.

## REFERENCES

1. Guglietta A, Hervada T, Nardi C, and Lesch A. Effect of platelet-derived growth factor on indomethacin-induced gastric lesions in rats. *Scand J Gastroenterol* 1992, 27: 673—676.
2. Folkman J, Szabo S, Stovroff M, Mc Neil P, Li W, and Shing Y. Duodenal ulcer—discovery of a new mechanism and development of angiogenic therapy that accelerates healing. *Ann Surg* 1991, 214: 414—427.
3. Szabo S, Folkman F, Vattay P, Morales RE, Pinkus GS, and Kato K. Accelerated healing of duodenal ulcers by oral administration of a mutein of basic fibroblast growth factor in rats. *Gastroenterology* 1994, 106: 1106—1111.
4. Konturek SJ, Brzozowski T, Majka J, Dembinski A, Slomiany A, and Slomiany BL. Transforming growth factor alpha and epidermal growth factor in protection and healing of gastric mucosal injury. *Scand J Gastroenterol* 1992, 27: 649—655.
5. Konturek SJ, Dembinski A, Warzecha Z, Brzozowski T, and Gregory H. Role of epidermal growth factor in healing of chronic gastroduodenal ulcers in rats. *Gastroenterology* 1988, 94: 1300—1307.
6. Ernst H, Konturek P, Hahn EG, Brzozowski T, and Konturek SJ. Acceleration of wound healing in gastric ulcers by local injection of neutralizing antibody to transforming growth factor B1. *Gut* 1996, 39: 172—175.
7. Schmassmann A, Stettler Ch, Poulson R, Tarasova N, Hirschi C, Flogerzi B, Matsumo K, Nakamwa T, Halter F. Roles of hepatocyte growth factor and its receptor during gastric ulcer healing in rats. *Gastroenterology* 1997, 113, 1858—1872.
8. Phole T, Shahin M, Domschke W, Konturek JW. Effect of basic fibroblast growth factor on gastric ulcer healing and its own mRNA expression. *Aliment Pharmacol Ther* 1999, 13: 1543—51.

9. Ernst H, Müller M, Paulus A, Hahn EG, Ell C. Immunohistochemical localization of basic fibroblast growth factor in the normal adult gastrointestinal tract. *Eur J Gastroenterol Hepatol* 1994, 6: 559–564.
10. Beauchamp RD, Barnard JA, McCutchen CM, Cherner JA, and Coffey RJ. Localization of TGF $\alpha$  and its receptor in gastric mucosal cells: implications for the regulatory in acid secretion and mucosal renewal. *J Clin Invest* 1990, 84: 1017–1023.
11. Cordon-Cardo C, Vlodavsky I, Haimovitz-Friedman A, Hicklin D, and Fuks Z. Expression of basic fibroblast growth factor in normal human tissues. *Lab Invest* 1990, 63: 832–840.
12. Konturek P, Ernst H, Brzozowski T, Müller M, Hahn EG, and Konturek JS. Expression of bFGF, EGF, TGF- $\alpha$  and their Receptors During Healing of Chronic Gastric Ulcerations in Rats. *Gut* 1995, (suppl 2) 37: A126.
13. Folkman J, and Klagsbrun M. Angiogenic factors. *Science* 1987, 235: 442–447.
14. Yayon A, Klagsbrun M, Esko JD, Leder P, and Ornitz DM. Cell surface, heparin-like molecules are required for binding of basic fibroblast growth factor to its high affinity receptor. *Cell* 1991, 64: 841–848.
15. Hull MA, Cullen DJ, Hudson N, and Hawkey CJ. Basic fibroblast growth factor treatment for non-steroidal anti-inflammatory drug associated gastric ulceration. *Gut* 1995, 37: 610–612.
16. Ascencio F, Hansson HA, Larm O, and Wadström T. Helicobacter pylori interacts with heparin and heparin-dependent growth factors. *FEMS Immunol Med Microbiol* 1995, 265–272.
17. Brzozowski T, Drozdowicz D, Szlachcic A, Pytko-Polonczyk J, Majka J, Konturek SJ. Role of nitric oxide and prostaglandins in gastroprotection induced by capsaicin and papaverine. *Digestion* 1993, 54: 24–31.
18. Hirose H, Takeuchi K, Okabe S. Effect of indomethacin on gastric mucosal blood flow around acid-induced ulcers in rats. *Gastroenterology* 1991, 100: 1259–1265.
19. Ernst H, Grunert S, Schneider HT, Beck WS, Brune K, Hahn EG. Distribution of extracellular matrix proteins in indomethacin induced lesions in the rat stomach. *Scand J Gastroenterol* 1995, 30: 847–853.
20. Konturek SJ, Brzozowski T, Majka J, Pawlik W, Stachura J. Omentum and basic fibroblast growth factor in healing of chronic gastric ulcerations in rats. *Dig Dis Sci* 1994, 39: 1064–1071.
21. McNeil PL. Cellular and molecular adaptations to injurious mechanical stress. *Trends in Cell Biol* 1993, 3: 302–307.
22. Kusstatscher S, Sandor Z, Satoh H, and Szabo S. Inhibition of endogenous basic fibroblast growth factor (bFGF) delays duodenal ulcer healing in rats: Implication for a physiological role of bFGF. *Gastroenterology* 1994, (suppl 1) A113.

Received: April 17, 2001

Accepted: July 9, 2001

Author's address: Dr. H. Ernst, Department of Gastroenterology, Carl-Thiem-Klinikum, Postfach 100 363, 03003 Cottbus, Germany.

E-mail: 4.Med.Klinik@ctk.de